



## Modern Management of Hidradenitis Suppurativa

### Disclosure

---

This program and the presentation contents are consistent with current guidelines and evidence base. The speaker is presenting the program on behalf of the Hidradenitis Suppurativa Foundation and will share their personal disclosures or conflicts.

Joslyn S. Kirby, MD, MS, MEd

Department of Dermatology, Penn State Milton S. Hershey Medical Center, Hershey PA

Conflicts & Financial Disclosures for HS: Speaker: AbbVie, Janssen, UCB; Consultant: AbbVie, Amgen, Incyte, Insmed, Janssen, Guidepoint, Moonlake, Novartis, UCB; Grants: NIH, Incyte; President, Hidradenitis Suppurativa Foundation

## Objectives

---

- **Understand** chronic, intermittent and immune-mediated nature of HS
- **Manage** acute treatment of HS flares
- **Develop** a plan for first-line maintenance therapy to 'bridge' the patient until they see a provider who can manage their HS

---

## Impact of HS

*"It became a nightmare. I was suffering physically and emotionally"*

## Impact of HS

- **Impacts of HS compared to other chronic conditions**
  - Quality of Life is worse than psoriasis, eczema
  - Hospital readmission rates are comparable to CHF
- More use of high-cost care such as ED, Urgent care, Inpatient compared to those with psoriasis or neither
- Frequent flares result in riding “roller coaster from hell” and cause missed work and/or school



Edigin, E. et al., JAAD. 2021; 21:2175-7.  
Kirby, J. et al., JAMA Dermatol. 2014; 150:937-944.

Matusiak, L. et al., JAAD. 2010; 62:706-708.  
Garg, A., et al., JAAD. 2020; 82:366-376.

5

## Impact of HS

### Challenges & Delays

- Average of 5 providers over 17 visits prior to diagnosis
- Mean delay in diagnosis is 7-10 years
- Work Impact: Mean 34 missed days/year, 10% fired, 23% missed promotion



Garg, A. et al., JAAD. 2020; 82:366-376  
Tzellos, T. et al., BJD., 2019; 181:147-154  
Matusiak, L. et al., Dermatol Clin 2016; 34:7-16.

6

# Clinical Manifestations & Diagnosis

*"It took me twenty years to get a correct diagnosis and I had to see a lot of specialists before I found someone... who is familiar with this condition."*

Willems, D. et al., Patient. 2021; Aug 9: 1-12.

7

## HS Statistics



- Occurs in ~1-4% of people 
- Higher prevalence in African Americans (6.4%) vs Caucasians (3.9%) 
- 3:1 Female : Male 
- Onset typically in early 20s, can also present in adolescents and older adults 

Jemec GBE. N Engl J Med. 2012;366(2):158-164  
Shahi V, et al. Dermatology. 2014;229(2):154-158

Vazquez BG, et al. J Invest Dermatol. 2013;13(1):97-103  
Reeder VJ, et al. J Invest Dermatol. 2014;134(11):2842-2843

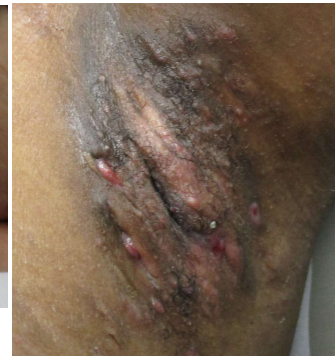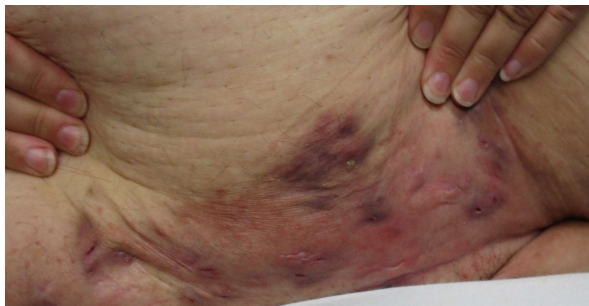
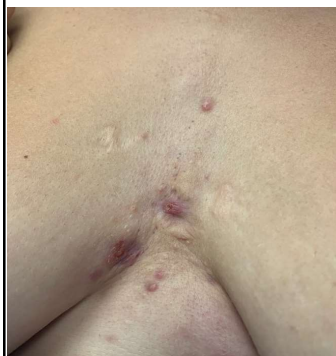8

## Clinical Characteristics



Symptoms: Pain, Drainage, Malodor, Itch

Signs: Inflammatory nodules & abscesses, scars, tunnels, comedones in typical locations, such as the axillae, chest & breasts, genitals, thighs, and buttocks



Recurrent and persistent inflammatory nodules, abscesses, and tunnels involving the intermammary chest, pannus, and axilla.

Shivankevich J, et al. J Am Acad Dermatol. 2014;71(6):1144-1150.

Van der Zee HH, et al. J Am Acad Dermatol. 2015;73: S23-S26.

9

## Diagnosis: 2 Questions to ask



1. Have you had outbreaks of boils during the last 6 months in the underarm, groin, or genitals?

YES

2. Where and how many boils have you had?

2

Sensitivity: 90%; Specificity: 97%;

**Positive Predictive Value: 96%\***

Vinding et al., Br J Dermatol. 2014;170:884-889.

10

# HS Pathogenesis

HS is a Chronic Inflammatory Skin Disease

*"I was told that the lesion was infected..."*

11

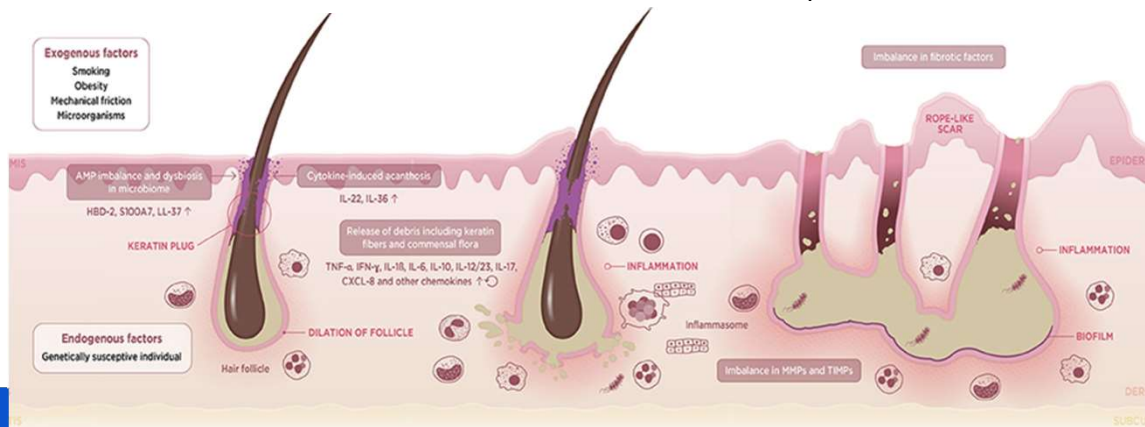
## HS is a chronic inflammatory skin disease



(1) Follicular occlusion and dilation

(2) Follicular rupture and immune response

(3) Chronic state with recurrent lesions and persistent tunnels



Courtesy of Vossen ARJV et al. Front Immunol. 2018;14:9:2965

12

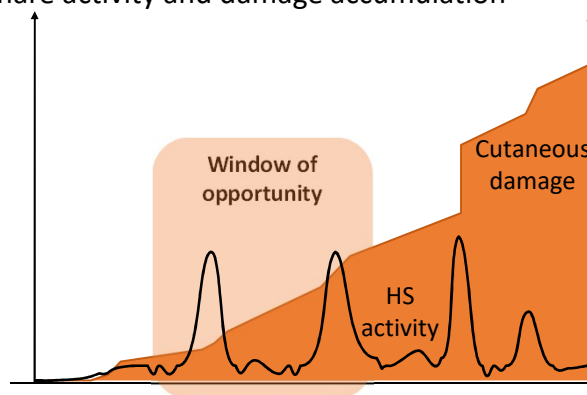
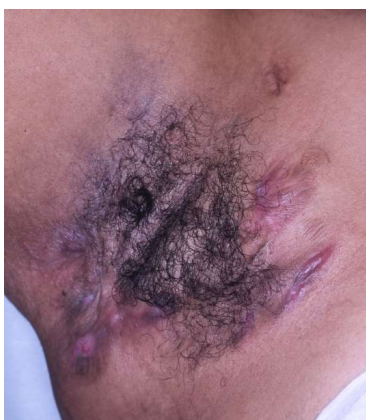# HS Management

*"I was told that they weren't sure what to do with me."*

## HS Management: Dual Strategic Objectives



1. Relieve symptoms from acute flares
2. Maintenance therapy to minimize flare activity and damage accumulation



Marotrell A, et al. Actas Derm 2016;107;(Suppl. 2):32-42, clinical image from Steven Daveluy, MD

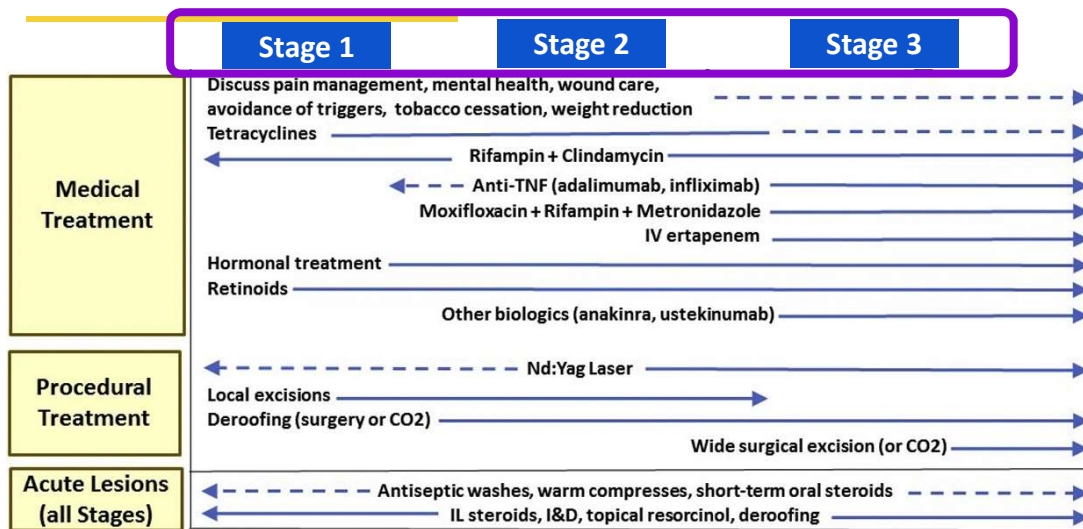
# Hurley Staging



| Stage 1   | Stage 2   | Stage 3  |
|---|---|--|
|   |   |  |
| Single or multiple separate lesions without tunneling or scarring | Single or multiple lesions, some with tunnel formation and scarring | Diffuse involvement of an area with multiple interconnected tunnels and scarring |

# Clinical Management Guidelines for HS

Free Download at:  
[www.hs-foundation.org](http://www.hs-foundation.org)



Alikhan et al., J. Am. Acad. Dermatol. 2019;81:76-90  
 Sayed et al., J. Am. Acad. Dermatol. 2019;81:91-101

# HS Flare Therapy

HS is a Chronic Inflammatory Skin Disease

*"Because of the location of the boil, I was really embarrassed to go (to the ER); but I was in so much pain."*

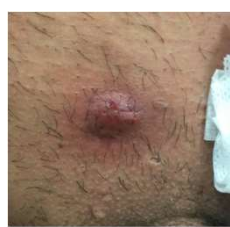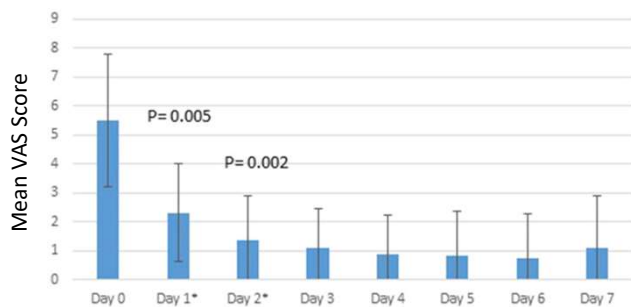
17

## What to do NOW

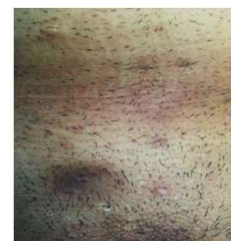|             | Anti-inflammatory     | Anti-microbial       |
|-------------|-----------------------|----------------------|
| Localized   | Intralesional Steroid | I&D                  |
| Generalized | Prednisone            | Systemic Antibiotics |

## Flare Therapy - Intralesional Steroid

Intralesional triamcinolone (Kenalog) 10-40mg/mL for inflammatory nodules, small abscesses and draining tunnels can significantly reduce redness, size, suppuration, edema, and pain



Baseline



Day 7



Riis et al., *J. Am. Acad. Dermatol.* 2016;75: 1151-55

19

## I&D - yes numb it, don't pack it

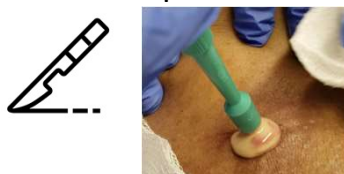1. You CAN numb pus



3. Don't pack it



2. I&D - Scalpel or Punch tool



4. Set expectations – Treats current pain, doesn't stop recurrence



Bourne CL et al. *J Emerg Med.* 2014;47(3):367-71 O'Bright NE et al. *J Okla State Med Assoc.* 2017; 110(2):78-79

20

## What to do NOW

|             | Anti-inflammatory     | Anti-microbial       |
|-------------|-----------------------|----------------------|
| Localized   | Intralesional Steroid | I&D                  |
| Generalized | Prednisone            | Systemic Antibiotics |



21

## Flare Therapy: Systemic antibiotics

Easy to prescribe, good short-term safety

- **Doxycycline**

- 100 mg p.o. BID
- AEs: GI upset, photosensitivity

- **Clindamycin**

*(if does not tolerate or previously failed tetracycline antibiotics)*

- 300mg p.o. BID
- AEs: GI upset, C. diff (rare)

**1-2 weeks for a flare  
Or for 12 weeks to be a bridge**



Sayed et al., Obstet. Gynecol. 2021;80:731-741.  
Caposiena Caro et al., J Am Acad Dermatol. 2019;80:1314-21.

van Straalen KR et al. J Am Acad Dermatol 2021;85:369-78

22

## Prednisone

---

- Consider oral prednisone for multiple lesions, multiple body sites
- Prednisone 0.5-0.7mg/kg for 1-3 weeks
- With or without oral antibiotics
- Avoid frequent or long-term use



Zouboulis CC et al. J Eur Acad Dermatol Venereol. 2015;29:619-644

23

---

## Maintenance Therapy

Improve baseline disease control and reduce flares as a bridge to specialized care

24

## Treatment Step #1 – Give Information

### Debunking Myths

- ✗ HS is an infection & contagious
- ✗ Weight loss will cure HS
- ✗ Smoking cessation will stop HS
- ✗ Better hygiene will stop HS

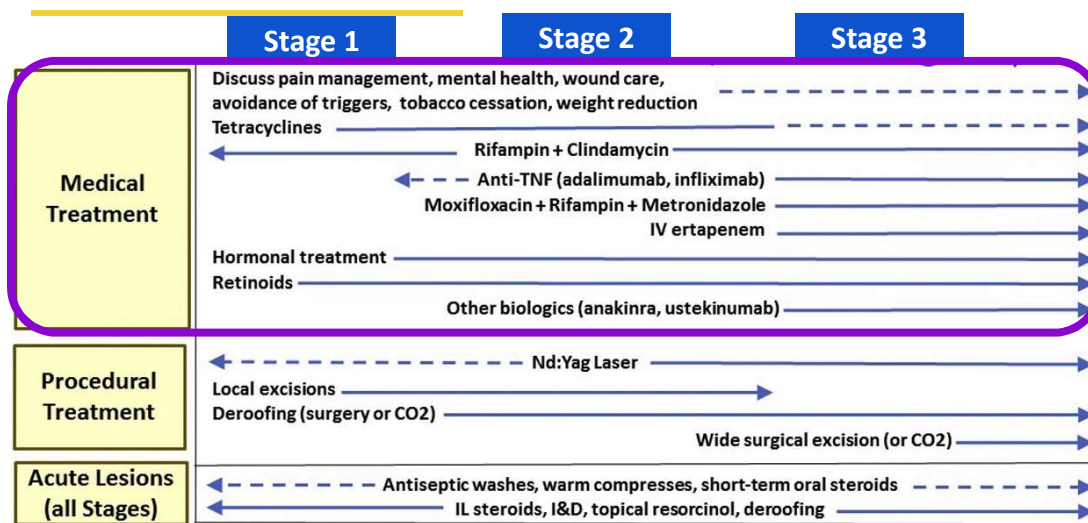
Not true!



25

## Clinical Management Guidelines for HS

Free Download at:  
[www.hs-foundation.org](http://www.hs-foundation.org)



Alikhan et al., J. Am. Acad. Dermatol. 2019;81:76-90  
 Sayed et al., J. Am. Acad. Dermatol. 2019;81:91-101

26

## Maintenance Therapy - Topicals



- Can be used for all stages, may not be sufficiently effective
- Over-the-counter washes
  - Chlorhexidine
  - Benzoyl peroxide
  - Zinc pyrithione
- Topical antibiotics
  - Clindamycin 1% solution, cream, gel or swabs
  - Used with antiseptic washes to reduce antibiotic resistance

Alikhan et al., J. Am. Acad. Dermatol. 2019;81:91-101

27

## Maintenance Therapy - Systemic



Bridge Therapy is a 'Long-ish' Antibiotic Course (12-ish weeks)

- **Doxycycline**
  - 100 mg p.o. BID
  - Cautions: GI upset, Photosensitivity
- **Clindamycin**
  - 300 mg p.o. BID
  - *Consider if previously failed tetracycline antibiotics*

Alikhan et al., J. Am. Acad. Dermatol. 2019;81:91-101

28

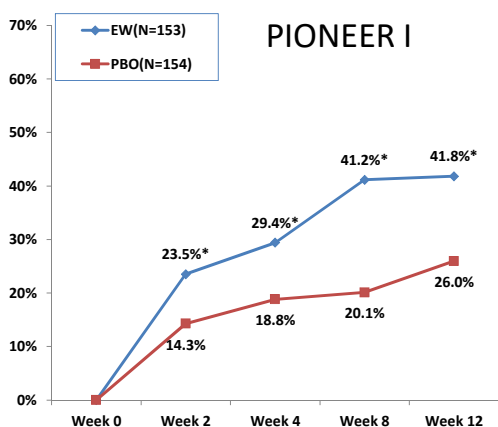
## On the other side of the Bridge...



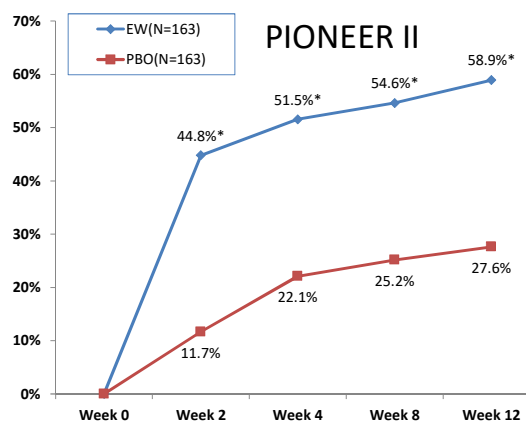
| Stage 1  | Stage 2   | Stage 3   |
|--|---|---|
|  |   |   |
| <p><b>Stabilize with</b> Topical/PO Antibiotics or ILT + pain therapy + Wound Care</p> <p><b>Bridge to</b> metformin, spironolactone, and others</p> | <p><b>Stabilize with</b> PO Antibiotics +Pain therapy + Wound Care</p> <p><b>Bridge to</b> biologic, procedures</p> | <p><b>Stabilize with</b> PO/IV Antibiotics +Surgery Consult + Prednisone+ Pain therapy +Wound Care</p> <p><b>Bridge to</b> biologic, procedures</p> |

29

## FDA-Approved Therapy - Adalimumab



\*: Statistically significant with P-value less or equal to 0.05



Kimball et al. N. Engl. J. Med. 2016;375:422-34

30

## Maintenance Therapy – Pain Management

- *Treat the HS!*
- Acetaminophen, NSAIDs
- Topical anesthetics
  - Preparation H (lidocaine) and Boil Ease (benzocaine), and others
- Consider gabapentin, pregabalin, duloxetine, venlafaxine
- Tramadol is an alternative to conventional opioids
- Consider collaboration with pain management specialist

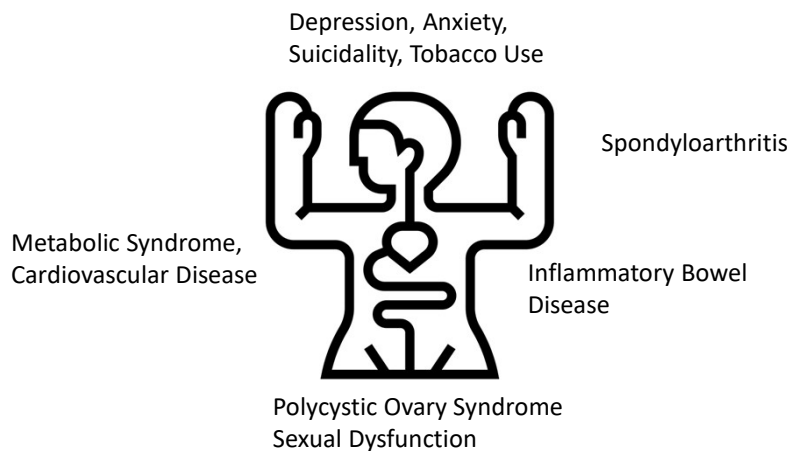


Garg A et al. J Am Acad Dermatol 2020;82:366-76  
Scheinfeld, Dermatol Online J. 2013;19:2016

van Straalen KR et al. J Am Acad Dermatol 2021;85:369-78  
Savage KT et al. J Am Acad Dermatol. 2021;85(1): 187-199 <sup>31</sup>

## HS is more than Skin Deep

**Non-cutaneous comorbidities to screen for:**



Garg A, et al. J Am Acad Dermatol. 2021 Jan 23:S0190-9622(21)00213-9. doi: 10.1016/j.jaad.2021.01.059. Online ahead of print.

32

## Summary

- HS is a chronic inflammatory disease with intermittent flares
- Treatment is combines medicines and procedures, anti-inflammatories and antibiotics, as well as acute and chronic interventions
- First-line maintenance therapy includes doxycycline and other antibiotics
- Referral to someone who is familiar with HS is crucial for long-term management, though multiple disciplines are needed to fully manage people with HS



33

## Thank you



HS Foundation



HS-Foundation.org



@hsforg

@HidradenitisSuppurati  
vaFoundation

34