

Understanding Brachial Plexus Injury: A Multidisciplinary Approach to Diagnosis and Management

Rachel Glowaski, PT, DPT

Continuing Medical Education Credit Information

- **Activity Description/Statement of Need:**

This course is designed to provide a comprehensive overview of brachial plexus injury diagnosis and management. This course will highlight the critical role of early recognition, appropriate and timely referrals, and multidisciplinary care approaches for optimized patient outcomes. Participants will review topics including anatomy, common mechanisms of injury, patient presentations, and surgical and non-surgical approaches. Emphasis will be placed on rehabilitative management.

- **Target Audience: All Providers**

Designation Statement

- It is St. Luke's University Health Network policy to ensure balance, independence, objectivity and scientific rigor in all of our sponsored educational programs. Faculty and all others who have the ability to control the content of continuing medical education activities sponsored by the St. Luke's Hospital & Health Network are expected to disclose to the audience whether they do or do not have any real or apparent conflict(s) of interest or other relationships related to the content of their presentation(s).
- The St. Luke's University Health Network is accredited by the Pennsylvania Medical Society to provide continuing medical education for physicians.
- The St. Luke's University Health Network designates this live educational activity for a maximum of 1 AMA PRA Category 1 Credits™. Physicians should only claim credits commensurate to the extent of their participation on the activity.

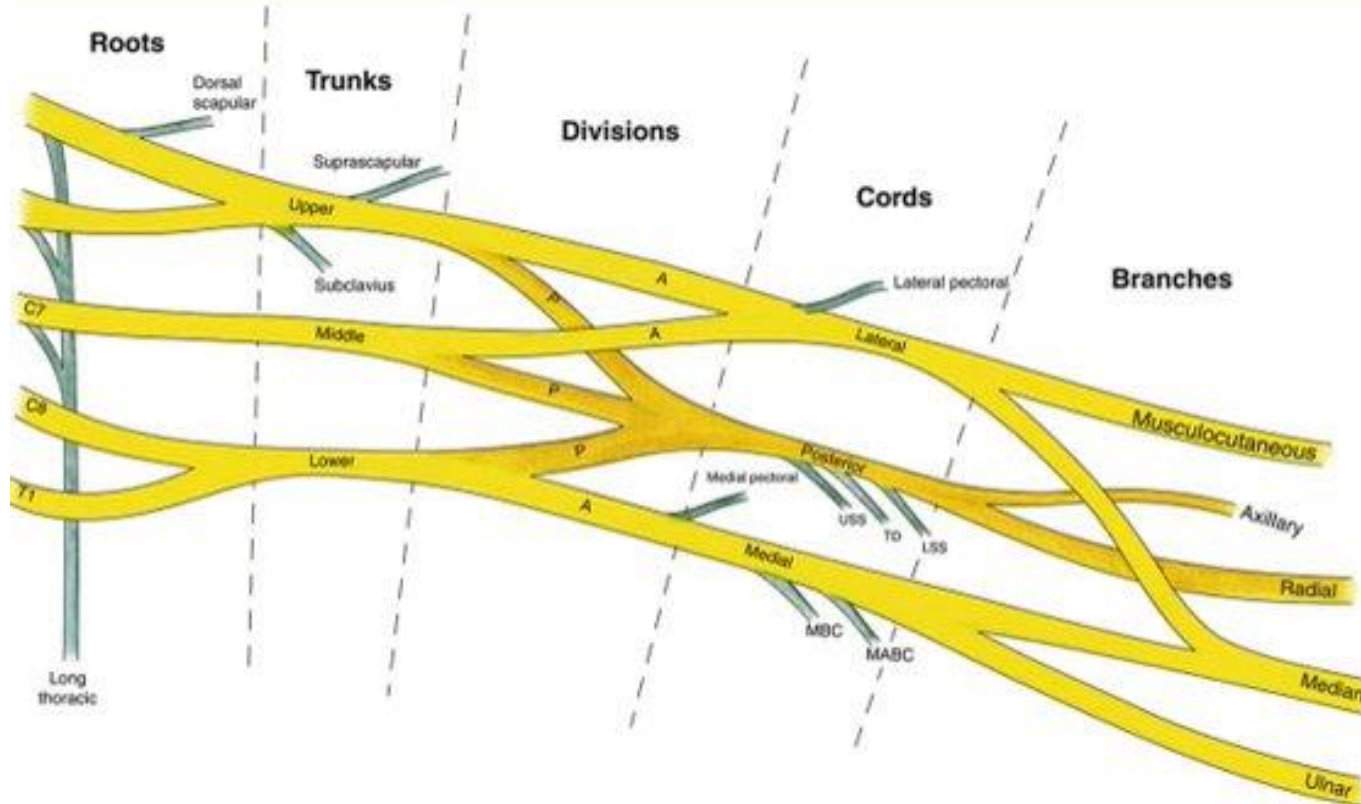
Disclosure Information

- The Planners involved in this activity have no relevant financial relationships to disclose.
- The Faculty/Presenters involved in this activity have no relevant financial relationships to disclose.

Learning Objectives

- Clinicians will be able to describe anatomy and function of the brachial plexus as it relates to injury mechanisms and clinical presentations.
- Clinicians will be able to identify key signs and symptoms of brachial plexus injury leading to appropriate and timely referrals.
- Clinicians will become familiar with surgical interventions as it relates to various levels of injury.
- Clinicians will be able to demonstrate appropriate prescription for orthoses, splinting/ positioning techniques and adaptive strategies to support healing and functional independence.
- Clinicians will be able to identify evidence-based therapeutic interventions to address motor-recovery and sensory re-education in patients with brachial plexus injury.
- Clinicians will be able to identify psychosocial challenges and provide the patient with appropriate resources/ education.

Anatomy of the Brachial Plexus



Level of Injury Classification

- Roots
 - Preganglionic → motor loss
 - Postganglionic → motor and sensory loss
- Trunks
- Divisions
- Cords
- Peripheral Nerves

Pattern of Injury Classification

- Supraclavicular vs. Infraclavicular
 - Supraclavicular lesions → result from a force pulling the head towards the opposite shoulder
 - Supraclavicular lesions occur about 75% of the time with adult BPI
 - Infraclavicular lesions → commonly occur from forceful abduction of the arm away from the body OR with fractures/ dislocations
 - Often incomplete injuries involving cords or peripheral nerves

Supraclavicular Lesion Pattern of Loss

Supraclavicular Lesion	Motion Lost
Upper arm (C5-6 roots)	Shoulder abduction, elbow flexion
Extensive upper arm (C5-C7 roots)	Shoulder abduction, elbow flexion and extension, wrist extension
Total arm (C5-T1 roots)	Flail arm, lacking all motion from shoulder to hand

Infraclavicular Lesion Pattern of Loss

Infraclavicular Lesion	Motion Lost
Lateral cord (musculocutaneous nerve)	Elbow flexion
Medial cord (median and ulnar nerves)	Finger flexion and intrinsic musculature
Posterior cord (axillary and radial nerves)	Shoulder abduction (caused by lack of deltoids but will still have function of the infra and supraspinatus), elbow and wrist extension

Etiology

- Males > females
- Age: 19-34
- MOI:
 - Most commonly following **motorcycle accidents**
 - High velocity accidents
 - Crush injuries
 - Lacerations
 - Gunshot wounds
 - Fractures
 - Dislocations of the shoulder
 - Iatrogenic injury
 - Radiation

Diagnostics

- Radiographs
- Computed Tomography Myelography (CT scan with contrast)
- MRI
- Ultrasound
- EMG

Degree of Injury

Injury	Pathophysiology	Examination Findings	Nerve Studies	Prognosis	Example
Neurapraxia (Seddon)	Reversible conduction block	Motor paralysis: complete but reversible	Distal nerve conduction: present	Good	Chronic nerve compression injury
First degree (Sunderland)	Localized segmental demyelination	Muscle atrophy: minimal	Motor unit action potential: absent	Full recovery usually within days to 2-3 weeks	Carpal tunnel syndrome
	Schwann cells dysfunction	Sensory alteration: minimal	Fibrillation: sometimes detectable		
Axonotmesis (Seddon)	Interruption of axon continuity	Motor paralysis: complete	Distal nerve conduction: absent	Fair	Crush injury
Second degree (Sunderland)	Preserved nerve sheath	Muscle atrophy: progressive	Motor unit action potential: absent	Full recovery possible without surgery	
	Wallerian degeneration	Sensory alteration: complete	Fibrillation: present		
Third degree (Sunderland)	Endoneurium disrupted Perineurium and epineurium intact	Same as second degree	Same as second degree	Same as second degree	
Fourth degree (Sunderland)	Endoneurium and perineurium disrupted Epineurium intact	Same as second degree	Same as second degree	Same as second degree	
Neurotmesis (Seddon)	Axon, myelin, and connective tissue damaged	Same as second degree	Same as second degree	Poor	Transection injury
Fifth degree (Sunderland)	Disruption of the endoneurium, perineurium, and epineurium			Surgery required; full functional recovery often not possible	Lacerations

Care Team

Peripheral
Nerve Surgeon
(team leader)

Physicians
from other
subspecialties

Radiologists

Hand therapy
(PT/OT)

Pain
management

Mental Health

Social Work

Patient/ family
members

Subjective Assessment

- Concomitant injuries
- Previous surgeries
- Previous treatments: sling, orthosis
- Support system
- Psychological Sequela
- Occupational profile

Physical Assessment

- Posture/joint contracture/ muscle atrophy
- ROM
 - Consider if patient had any dislocations or fractures
- Strength Testing
 - Brachial Plexus Nerve Muscle Record
 - If no active muscle contractions can use tender muscle sign (TMS)

Physical Assessment Continued

Brachial Plexus Nerve Muscle Record Page 2 of 5

Provider: _____ Pager: _____

Currently involved Left (L) Right (R) Both (B)

Brachial Plexus	DATE	Side involved
Tinel's in Neck		
Horner's Sign		
Diaphragm		
EMG		
Pain		

Level	Muscle	Grade
C3, C4, XI	Upper trapezius	
C3, C4, XI	Middle trapezius	
C3, C4, XI	Lower trapezius	
C3, C4, C5	Levator scapulae	
C4, C5	Rhomboids	
C5, C6	Supraspinatus	
C5, C6	Infraspinatus	
C5, C6, C7	Teres anterior	
C5, C6	Teres major	
C5, C6	Subscapularis	
C5, C6, C7	Clav. pect. major	
C6, C7, C8, T1	Stern. pect. major	
C6, C7, C8, T1	Pect. minor	
C6, C7, C8	Latissimus dorsi	
C5, C6	Biceps & Brachialis	
C5, C6, C7	Coracobrachialis	
C5, C6	Deltoid anterior	
C5, C6	Deltoid middle	
C5, C6	Deltoid posterior	
C5, C6	Teres minor	
C7, C8, T1	Pronator quadratus	
C6, C7	Pronator teres	
C6, C7	Flex. carpi rad.	
C7, C8, T1	Flex. dig. prof. II, III	
C7, C8, T1	Flex. dig. sup.	
C7, C8, T1	Palmaris longus	
C7, C8, T1	Flex. pol. long.	
C6, C7, C8, T1	Flex. pol. brev. (long)	
C6, C7, C8, T1	Abdu. pol. brev.	
C8, T1	Opponens pollicis	
C8, T1	Lumbricals, 1, 2	
C6, C7, C8	Triceps	
C5, C6	Supinator	
C5, C6	Brachioradialis	
C6, C7	Ext. carpi rad. long.	
C6, C7, C8	Ext. carpi rad. brev.	
C7, C8	Ext. carpi ulnaris	
C7, C8	Ext. dig. com.	
C7, C8	Ext. dig. minimi	
C7, C8	Ext. int. prop.	
C7, C8	Ext. pol. longus	
C6, C7	Ext. pol. brev.	
C6, C7	Abdu. pol. long.	
C7, C8, T1	Flex. carpi uln.	
C7, C8, T1	Flex. dig. prof. IV, V	
C8, T1	Abdu. dig. minimi	
C8, T1	Add. pol.	
C8, T1	Opp. dig. minimi	
C8, T1	1 Dorsal Interosseous	
C8, T1	2 Dorsal Interosseous	
C8, T1	3 Dorsal Interosseous	
C8, T1	4 Dorsal Interosseous	
C8, T1	1 Palmar Interosseous	
C8, T1	2 Palmar Interosseous	
C8, T1	3 Palmar Interosseous	
C9, T1	Lumbricals 3,4	
C8, T1	Flex. pol. brev. (short)	

Grade	Degree of Muscle strength	Descriptive Term
0 = Zero	No palpable contraction	Nothing
1 = Trace	Muscle contracts, but part does not move	Trace
2 = Poor	Partial movement of part with gravity eliminated	With gravity eliminated
2 = Fair	Muscle moves the part through full range of motion against gravity	Against gravity
4 = Good	Full range of motion against gravity plus added resistance	Near normal
5 = Excellent	Normal strength	Normal

Key Note on Legend bar for draw tool
X = Avulsion O = Rupture == = Stretch

Physical Assessment Continued

Muscle	Action	Innervation
Trapezius	Shrug the shoulders	Spinal accessory nerve
Sternocleidomastoid	Turn head from side to side	Spinal accessory nerve
Rhomboids	Retract the scapula	Dorsal scapular nerve
Serratus Anterior	Push against a wall with extended arms	Long thoracic nerve
Pecs	Resisted flexion and ADD of the UE	C5-C7 and medial pectoral nerves C8-T1
Latissimus Dorsi	Resisted ADD	Thoracodorsal nerve C6-8

Physical Assessment Continued

UQ Myotome Testing

(Deltoid) resisted ABD	Axillary nerve
Elbow flexion	Musculocutaneous nerve C5-C7
Elbow, wrist, and digital extension	Radial nerve C6-C8 with variable contributions from C5-T1
Wrist and digital flexion	Median nerve C6-T1 and Ulnar nerve C8-T1
Intrinsic hand and thumb motion	Median and Ulnar nerves

Physical Assessment Continued

- Sensibility Testing
 - The 10 test
 - Semmes- Weinstein
 - 2-point discrimination
 - Vibration

Presentation of Supraclavicular Upper Trunk Injury

- Pain:
 - C2 distribution of cranium
 - Across trapezius ridge
 - Medial border of scapula
 - Headache
 - TMJ
 - Ear
 - Muscle Spasms common in SCM, scalene, and trapezius
- Exam Findings:
 - Drooped shoulder
 - Weakness of UT, serratus, and rhomboids
 - Symptoms intensified with deep pressure over suprascapular notch and percussion at the supraclavicular fossa

Presentation of Supraclavicular Lower Trunk Injury

- Pain:
 - Dull ache/ paresthesias of the 4th and 5th digits and medial forearm
- Exam Findings:
 - Weakness of hand intrinsic, APB, OP, and dorsal/ volar interossei
 - Discomfort with pressure over the clavicle (ie. Bra strap)
 - Report of dropping things

Presentation of Infraclavicular Medial Cord Injury

- Pain:
 - Supraclavicular and infraclavicular fossa
 - Paresthesias of the medial upper arm, forearm, and 4th and 5th
- Exam Findings:
 - Pain with pressure over supraclavicular and infraclavicular fossa
 - + ULTT with median and ulnar nerve bias
 - Motor loss → finger flexion, intrinsics

Presentation of Infraclavicular Lateral Cord Injury

- Pain:
 - Pain in the infraclavicular fossa; radiates into the lateral and anterior chest wall
 - Paresthesia to thumb, index, and radial middle finger
- Exam Findings:
 - + ROOS, pain with pressure to lateral clavicle
 - ULTT with median, musculocutaneous, and axillary nerve bias
 - Motor loss → elbow flexion

Presentation of Infraclavicular Posterior Cord Injury

- Pain:
 - Pain in the triceps region and lateral epicondyle at the entrance of the PIN
 - Paresthesia of the dorsoradial hand
- Exam Findings:
 - + to arcade of Frohse
 - + ULTT with radial nerve bias
 - Motor loss → shoulder ABD, elbow and wrist extension

Surgical vs. Nonsurgical Intervention

Indications

- MOI:
 - Sharp lacerations
 - Open crush injuries
 - Concomitant vascular injury
 - Iatrogenic causes
- Guiding Principles:
 - No potential for spontaneous recovery
 - Time from injury to motor sensory reinnervation
 - Irreversible motor endplate loss: 12-18 months

Surgical Interventions

- Neurolysis
- Nerve Grafting
 - Better outcomes if <10 cm defect
- Neurotization → procedure in which a nerve or fascicle of a working nerve is removed and attached proximally to a recipient (damaged nerve)
 - Extraplexal → donor from outside of the brachial plexus
 - *Intraplexal → donor from inside the brachial plexus
- Arthrodesis
- Tendon Transfer
- Functioning Free Muscle Transplantation → advanced microsurgical procedure that replaces damaged or missing muscles with functioning muscles from else where in the body

Nonsurgical Interventions

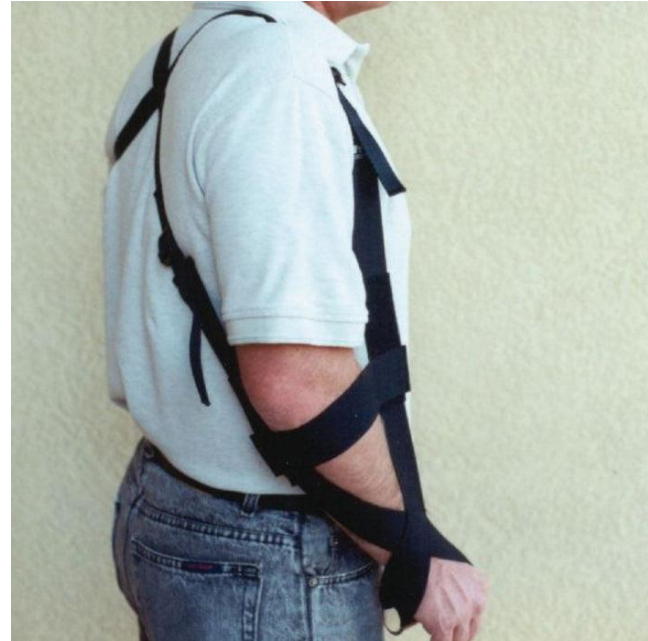- Goals of rehab:
 - Edema management
 - Pain management
 - Appropriate referrals
 - Stability via slings/ orthoses
 - Joint ROM
 - ADL instruction
 - Patient Education on outcomes/ expectations

Pain Management

- Can be assessed via Visual Analog Scale (VAS) and Numeric Rating Scale (NRS)
- Can be medically managed including but not limited to:
 - Central analgesics
 - Psychiatric medications
 - Narcotics
 - Hormones

Positioning/ Orthosis

- Positioning
 - Wedge foam/ pillow between the body and forearm
- Sling
 - Important for flail and weak UE
 - GivMohr sling will position the arm in slight external rotation
 - Should not impede healing of repaired/ healing structures
- Orthoses
 - Functional:
 - Wrist cock up
 - Radial Nerve Palsy
 - Opponens orthosis
 - Address or prevent contracture:
 - Intrinsic plus at night to prevent MP flexion contracture
 - Ulnar Palsy orthosis



Motor Re-education

- PROM > AAROM > AROM
 - Gravity eliminated – against gravity
 - Perform activities for short durations but high frequency
- Proprioceptive neuromuscular facilitation (PNF)
- Exercises that involve basic I/ADLs

Other Therapeutic Interventions

- Sensory reeducation
 - Mirror visual feedback
- Biofeedback/ E-stim
- Aquatic Therapy
- Taping
- Robotics

Outcomes/ Expectations

- Create realistic healing expectations based on patient presentation
 - Provide education on typical nerve regeneration timelines (1mm/day)
 - Proximal reinnervation occurring more quickly than distal
 - Discussion regarding likelihood of spontaneous recovery

Psychosocial Considerations

- Studies demonstrate that at least 1/3 of hand injured patients experience symptomatic PTSD, depression, and signs of mood disorder
- Must consider emotional and social support of patients following adult BPI especially that of **productive young males**
- Early screening/ referral to mental health specialists can allow depressive symptoms to be addressed while waiting for spontaneous recovery/ surgical recovery
- Monitor compliance to therapy during the later stages to prevent dangerous behaviors and be able to offer psychosocial assistance

Outcome Measures

- Post-traumatic Stress Disorder Check List (PCL-S)
- PHQ-8
- Impact of BPI questionnaire*
- Interpersonal Support Evaluation List (ISEL-12)

*proprietary outcome measure

PCL-S

- Standard 17 item self-reported assessment
- PTSD specific
- Scoring:
 - Rates how much a specific traumatic event has affected them over the past month
 - 1 (not at all) to 5 (extremely)
 - Total the score ranges from 12-85, higher score indicating more severe symptoms

PHQ-8

- 8 item assessment
- Depression specific
- Scoring:
 - Rates how often a specific symptom has bothered them over the past 2 weeks
 - 0 (not at all) to 3 (nearly every day)
 - Total score possible is 24
 - Total score correlates with level of depression
 - None (0-4)
 - Mild (5-9)
 - Moderate (10-14)
 - Moderately severe (15-19)
 - Severe (20-24)

*score of 10 or more indicates clinical depression

Impact of BPI Questionnaire

- Proprietary outcome measure
- Designed by Dr. Mancuso at the Center for Brachial Plexus and Traumatic Nerve Injury at the Hospital for Special Surgery
- Performed in 3 phases
- Measures disability using 3 subscales (symptoms, limitations, emotion) and expected improvement
- Scored 0-100; higher score indicating greater disability and greater expected improvement respectively
- Assesses multiple domains of patient well being

Interpersonal Support Evaluation List (ISEL-12)

- 12 item outcome measure
- Assesses perceptions of social support
- 3 subscales:
 - Appraisal support
 - Belonging support
 - Tangible support
- Scored 0-36; higher scores associated with higher perceived availability of social support

Resources

1. <http://www.ubpn.org>
2. <http://www.tbpi-group.org>

PATIENT CASE STUDY

Demographics/ MOI

- 18 yo male
- MOI:
 - Helmeted motorcycle accident versus truck on 10/30/24
 - Pt has no memory of the accident/ immediate events following
- Hospitalization: 10 days
 - Multiple traumas/ concomitant injuries
 - Positional hypotension
- Inpatient rehab: 9 days (admitted 11/9/2024)
 - PT/OT

Subjective Findings

- Date of IE: 11/25/24 (26 days since initial injury)
- Chief Complaint
 - Primary complaint of L UE weakness and tingling/ numbness into the L thumb and SF
 - Generalized pain secondary to injury
 - L hand 3/10 (tingling and burning)
 - L thigh 1/10
 - Cervical 2/10
- Presented to IE donning a sling for the L UE
 - Had been prescribed an OTC wrist brace but had not been donning
- Medications
 - 1000 mg Gabapentin 3x per day
 - Dilaudid PRN
- Moderate Assistance with all I/ADLs
- Hobbies:
 - Video games
 - Kayaking
 - Fishing

Patient Goals

- Return to fishing
- Return to driving
- Be able to play video games with controller and mouse/ keyboard
- Return to PLOF

Objective Findings

- Posture
 - Asymmetric rounded shoulders
 - Corrections of posture increased pain (increased L rib pain)
- Sensation
 - R light touch intact
 - L light touch diminished palmar aspect of LF (C7)

Objective Findings Continued

- AROM
 - L shoulder*
 - Flexion 50* (painful)
 - Abduction 80* (painful)
- PROM
 - R shoulder
 - Flexion 70* (painful)
 - Abduction 110* (painful)
 - ER at 45* 12* (painful)
 - IR NOT performed due to high reactivity
 - L shoulder*
 - Flexion 160* (painful)
 - Abduction 102* (painful)
 - ER 80* (painful)
 - IR 79*

* Limited due to high reactivity

MMT

	<u>Shoulder</u>		<u>Elbow</u>		<u>Wrist/Hand</u>	
	L	R	L	R	L	R
Flexion	2-/5	2+/5	2-/5	4-/5	0/5	4-/5
Abduction	2-/5	2+/5				
ER	2-/5	3-/5				
IR	2-/5	3-/5				
Upper Trapezius	4+/5					
Extension			2-/5	4-/5	0/5	4-/5
Radial Deviation					0/5	4-/5
Ulnar Deviation					0/5	4-/5
Supination			0/5	3+/5		
Pronation			0/5	3+/5		

Special Tests/ Palpation


- L shoulder
 - + sulcus sign: 1 finger subluxation
- Tender to palpate along entire L UE

Diagnostic Test Results

- Diagnostic Interpretation: **ABNORMAL STUDY**
- Electrodiagnostic evidence of brachial plexus injury, likely involving the medial cord and posterior cord most likely 2/2 traction injury. Does not appear to have electrodiagnostic evidence of injury to the lateral cord.

Treatment/ Recovery

- 12/4/24
 - Noted some return of intrinsics, Adductor Pollicis, FPB, Triceps, Pronators/Supinators, Wrist Flexors
 - Gravity eliminated, AAROM S/L
- 12/6/24
 - Able to flex fingers of L hand without quick stretch of the flexors
 - Manual Resistance: elbow flexion/extension
- 12/11/24
 - Lacking 37* of elbow extension with neural tension
 - Improve scapular control in S/L
 - Trace wrist extensors
 - Manual Resistance: shoulder IR/ER 0* shoulder ABD
- 12/18/24
 - Lacking 10* elbow extension
 - Progressed to supine L shoulder flexion and abduction AAROM
 - Increased neuromuscular control with supination and pronation
 - AROM scapular elevation/depression
 - Blocking of IPs was not successful secondary to poor extrinsic activation
 - EMG



Treatment/ Recovery Continued


- 12/20/24
 - Progressed to L Shoulder Flexion and Abduction in supine with Min A
 - PROM PIP/DIP IF/MF, pain and stiffness improved with repetition
 - RUE shoulder isometrics
- 12/23/24
 - Progressed to L shoulder flexion and abduction in standing
 - Required heavy use of mirroring/mental imagery of the contralateral limb
 - Excessive use of biceps observed with standing bicep curls in neutral
 - No return of extrinsic and wrist extensors
- 12/27/24
 - Decreased Gabapentin to 600 mg/day
 - Tingling and Numbness isolated to L palm, thumb, IF, and MF
 - Shoulder isometric holds at available end range
- 1/3/25
 - Active finger flexion of RF and LF
 - MCP/IP blocking
 - PROM wrist flexion/extension with tenodesis
 - Minimal muscle activation of L deltoid and L brachioradialis
 - Positive for median neural tension at 40 degrees elbow extension
 - Improved by 15 degrees following median nerve glide

Treatment/ Recovery Continued

- 1/7/25
 - 100 mg Gabapentin 3x/Day
 - Initiated opposition to the LF
 - Poor muscular endurance and stiffness of CMC joint
 - Activation of wrist extensors in gravity eliminated position
 - Limited L shoulder flexion and ER with pain at end range
 - Opposition, Putty, UBE, bent over tricep kickbacks
- 1/8/25
 - Palpable ECRL/ECRB muscle contraction
 - Increased FDS/FDP activity in L MF, RF, and LF
 - Median nerve glide, place and holds L wrist extension, towel scrunches, RD UD AAROM
- 1/15/25
 - No pain medication
 - Trace FDP of IF
 - Able to hold wrist extension in neutral in gravity eliminated position
 - Introduction to tenodesis grip
 - Applied KT Tape to wrist extensors
 - AAROM palmar ABD

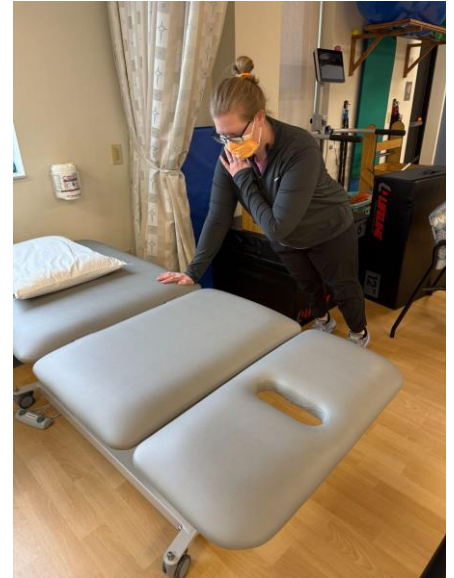
Treatment/ Recovery Continued

- 1/17/25
 - Improved ability to make a fist
 - Limited by thumb and IF
 - Weakness and joint stiffness
 - Placed 2nd MCP into flexion to improve isolated activation of FDP and FDS
 - Finger Web, shoulder rows/extensions
- 1/24/25
 - Utilized NMES for AAROM wrist extension activation
 - Demonstrated good carry over
 - Inclined weight bearing
 - Limited due to lack of full elbow extension
 - Prone Triceps
- 2/14/25
 - Able to make a full fist
 - Mild flexor lag at the DIP of IF
 - Difficulty with groove peg translation activity and digiflex
 - IF and RF
 - Therabar, resisted wrist flexion/extension



Treatment/ Recovery Continued

- 2/21/25
 - Theraband Shoulder D1/D2 PNF
 - Inclined plank
 - Alternating shoulder taps



Re-evaluation Objective Findings (2/28/2025)

- Sensation
 - Intact
- AROM
 - R shoulder WFL
 - L shoulder
 - Flexion 155 degrees
 - Abduction 160
 - ER 80 degrees
 - IR WFL
- PROM
 - R Shoulder all WFL
 - L Shoulder
 - Flexion 165 degrees
- Wrist and elbow ROM WFL
- MMT/Grip/pinch strength (next slide)
- 9 hole peg test
 - L= 18 seconds
 - R= 15 seconds

MMT

	<u>Shoulder</u>		<u>Elbow</u>		<u>Wrist/Hand</u>	
	L	R	L	R	L	R
Flexion	3+/5	3+/5	*	*	4+/5	5/5
Abduction	3+/5	3+/5				
ER	4-/5	4/5				
IR	3/5	4-/5				
Upper Trapezius	5/5					
Extension			4/5	4+/5	4+/5	5/5
Radial Deviation					5/5	5/5
Ulnar Deviation					5/5	5/5
Supination			4+/5	5/5		
Pronation			4+/5	5/5		

Additional Strength Testing

	<u>L</u>	<u>R</u>
Grip Strength	35	95
Key/Lateral Pinch	2	8
Palmar/Three-point pinch	2	14

Treatment/ Recovery

- Patient completed therapy after 5 months of therapy
- Greatest challenge psychologically was during these months
- Focused on grip strength and closed chain activities
- Discharged on 4/18/25

Patient Case Wrap Up

- Pt presented to IE following helmeted motorcycle accident versus truck on 10/30/24
- IE was limited due to multiple traumas, pain/ muscle guarding, and orthostatic BP
- Treatment was directed by spontaneous recovery, progressing from PROM >AAROM >AROM
- Pt had recovery of the median and ulnar nerve first and radial nerve last
- Spontaneous recovery was random
- Treatment for individuals with brachial plexus injuries should be individualized addressing primary impairments and addressing hobbies/ patient goals
- Provide appropriate healing timelines to create appropriate patient expectations

Questions?

References

- Bhat, S.G. *et al.* (2025) 'Enhanced Functionality Using a Powered Upper Extremity Exoskeleton in Patients with Brachial Plexus Injuries', *IEEE Transactions on Neural Systems and Rehabilitation Engineering*, 33, pp. 780–786. Available at: <https://doi.org/10.1109/tnsre.2025.3538175>.
- Chinchalkar, S.J. *et al.* (2018) 'The Use of Dynamic Assist Orthosis for Muscle Reeducation following Brachial Plexus Injury and Reconstruction', *Journal of Hand and Microsurgery*, 10(3), pp. 172–177. Available at: <https://doi.org/10.1055/s-0038-1642068>.
- Deisher, M. Surgical and Therapy Management of Adult Brachial Plexus Injuries. Virtual Hand to Shoulder Fellowship LLC.
- *Diagnosis and treatment - Mayo Clinic* (2025) *Mayoclinic.org*. Available at: <https://www.mayoclinic.org/diseases-conditions/brachial-plexus-injury/diagnosis-treatment/drc-20350241?p=1> (accessed: 25 August 2025).
- Dy, C.J., Brogan, D.M., Lee, S.K., Desai, M.J., Loeffler, B.J., Tuffaha, S.H. and PLANEt Study Group (2024). The Influence of Psychosocial Factors on Disability and Expected Improvement Before Surgery for Adult Traumatic Brachial Plexus Injury. *The Journal of hand surgery*, [online] 49(8), pp.729–735. doi:<https://doi.org/10.1016/j.jhsa.2023.05.023>.
- Free Functional Muscle Transfer. (2025, January 13). *Physiopedia*, . Retrieved 19:38, September 7, 2025 from https://www.physio-pedia.com/index.php?title=Free_Functional_Muscle_Transfer&oldid=364844.
- Hill, J.R. *et al.* (2021) 'Management of Adult Brachial Plexus Injuries', *The Journal of Hand Surgery*, 46(9), pp. 778–788. Available at: <https://doi.org/10.1016/j.jhsa.2021.05.008>.
- John Hopkins Medicine (2024) *Brachial Plexus Injury*, www.hopkinsmedicine.org. Available at: <https://www.hopkinsmedicine.org/health/conditions-and-diseases/brachial-plexus-injuries>
- Landers, Z.A. *et al.* (2018) 'The Psychological Impact of Adult Traumatic Brachial Plexus Injury', *The Journal of Hand Surgery*, 43(10), pp. 950.e1–950.e6. Available at: <https://doi.org/10.1016/j.jhsa.2018.02.019>.
- Li, H., Chen, J., Wang, J., Zhang, T. and Chen, Z. (2023). Review of rehabilitation protocols for brachial plexus injury. *Frontiers in Neurology*, 14. doi:<https://doi.org/10.3389/fneur.2023.1084223>.
- Prasad Biswal O, Nayak S and Kumar Das R (2023) Orthotic and Prosthetic Management in Brachial Plexus Injury: Recent Trends. *Frontiers in Spinal Neurosurgery*. IntechOpen. Available at: <http://dx.doi.org/10.5772/intechopen.109701>.
- Sakellariou, V.I., Badilas, N.K., Stavropoulos, N.A., Mazis, G., Kotoulas, H.K., Kyriakopoulos, S., Tagkalegkas, I. and Sofianos, I.P. (2014). Treatment Options for Brachial Plexus Injuries. *ISRN Orthopedics*, [online] 2014, pp.1–10. doi:<https://doi.org/10.1155/2014/314137>.
- Skirven, T.M. (2020) *Rehabilitation of the hand and upper extremity*. 7th edition S.L., 45–46, Elsevier.