

HAYSMED

Medical Terminology Week 1

This Photo by Unknown Author is licensed under CC BY-NC-ND This Photo by Unknown Author is licensed under CC BY

Chapters 1, 2, and 3

July 2024

Education
Kelly Cole EdD, RN, CNE

1

- Adapted from: Medical Terminology For Healthcare Professions
- Andrea Nelson & Katherine Greene
- Creative Commons Attribution OER
- <https://pressbooks.uwf.edu/medicalterminology/>

2

HAYSMED

Chapter 1 – Word Parts and Rules Objectives

- Identify word parts in medical terms
- Examine the rules for building medical terms

3

HAYSMED
Medical Terminology Is . . .

- Special vocabulary used by health care professionals for effective and accurate communication
- Based on Latin and Greek words

4

HAYSMED

Word Parts

- 1) PREFIX is the word part at the beginning that changes the meaning of the word
- 2) SUFFIX is the word part at the end that changes the meaning of the word
- 3) WORD ROOT is the central or foundational meaning of the word.
- 4) COMBINING FORM is the word root with a combining form vowel.

5

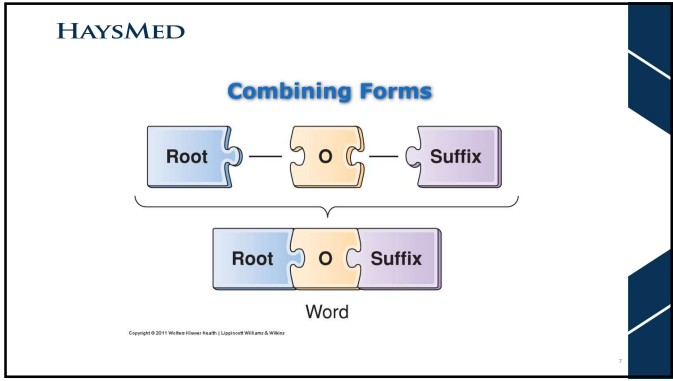
HAYSMED

Prefix — Root — Suffix

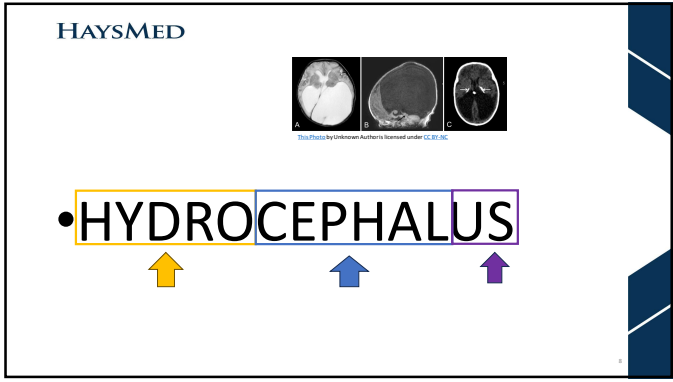
Word

Copyright © 2011 Wolters Kluwer Health | Lippincott Williams & Wilkins

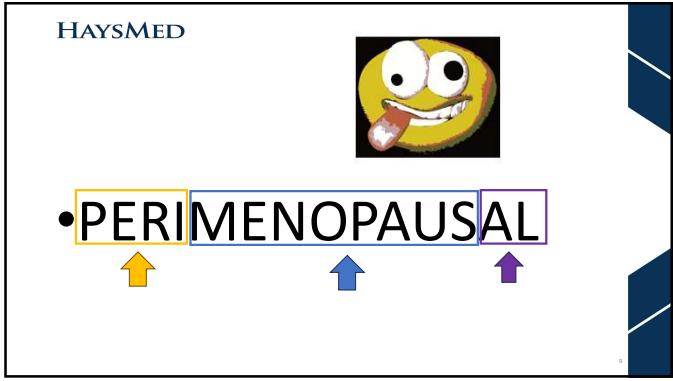
6



7



8



9

HAYSMED

Chapter 2 – Prefixes & Suffixes




- Understand the difference between a prefix and a suffix
- Differentiate prefixes that deal with body parts, color, direction
- Distinguish suffixes that deal with procedures

10

HAYSMED

PREFIXES

- Common General Descriptions
 - Eu
 - Contra
 - Auto
- Body Parts
 - cardi/o
 - Gastr
 - Aden
 - Cost
- Color
 - Chlor
 - Cyan
 - Erythr/o
- Properties/Shapes
 - Cry/o
 - Scolio
- Direction/Position
 - Infra
 - Meso
 - Dia
- Quantity/Quality
 - Olig/o
 - Tachy
 - Iso
 - Diplo
 - Brady








11

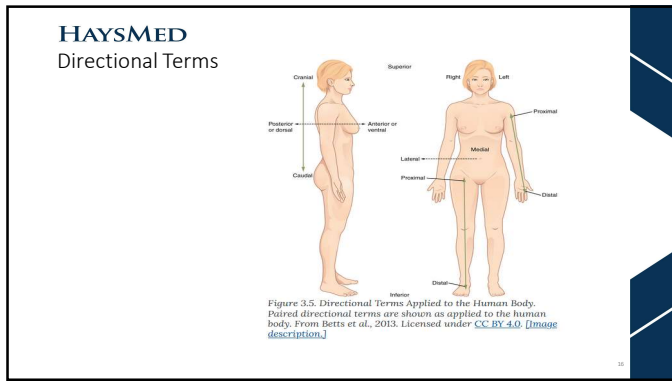
HAYSMED

SUFFIXES

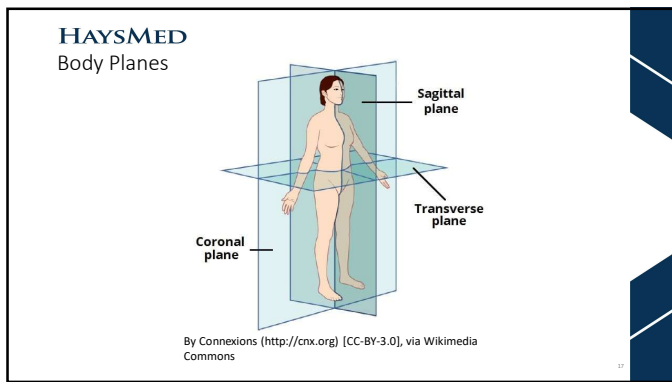
- Common General Descriptions
 - emia
 - cyte
 - megaly
 - stasis
- Procedures
 - ectomy
 - ostomy
 - otomy
 - scopy
 - gram
 - graph
 - graphy

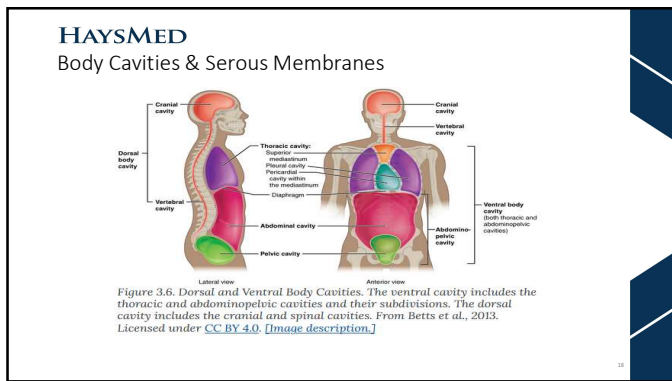
12



16



17



18

HAYSMED

Figure 14. Dorsal and Ventral Body Cavities. The cranial cavity includes the brain and olfactory bulbs and is located in the head. The thoracic cavity includes the heart and lungs and is located in the chest. The abdominopelvic cavity includes the abdominal and pelvic cavities and is located in the abdomen and pelvis.

• **ABDOMINOPELVIC**

19

HAYSMED

Abdominal Regions and Quadrants

(a) Abdominopelvic regions (b) Abdominopelvic quadrants

By OpenStax. Download for free at <http://cnx.org/content/col12146/48.35/1756a014c4848@3.0>, CC BY 3.0. <https://commons.wikimedia.org/wiki/index.php?curid=29624324>

20

HAYSMED

By OpenStax. Download for free at <http://cnx.org/content/col12146/48.35/1756a014c4848@3.0>, CC BY 3.0. <https://commons.wikimedia.org/wiki/index.php?curid=29624324>

• **HYPOCHONDRIAC**

21

HAYSMED

By Description. Download for free at <http://www.org/content/17/4e4ub-a075-45af-5855-f756d5-4c448d3>. CC BY 3.0. <https://commons.wikimedia.org/w/index.php?curid=29224324>

• **HYPOGASTRIC**

↑ ↑ ↑

22

HAYSMED

Tissue Membranes

Figure 3.8. Serous Membrane. Serous membrane lines the pericardial cavity and reflects back to cover the heart—much the same way that an underinflated balloon would form two layers surrounding a fist. From Betts et al., 2013. Licensed under CC BY 4.0 [Image description.]

Figure 3.7. Tissue Membranes. The two broad categories of tissue membranes in the body are (1) connective tissue membranes, which include synovial membranes, and (2) epithelial membranes, which include mucous membranes, serous membranes, and the cutaneous membrane. In other words, the skin. From Betts et al., 2013. Licensed under CC BY 4.0 [Image description.]

23

HAYSMED

Subcutaneous (SC) Injection

45° angle

skin
subcutaneous tissue
muscle


• **SUBCUTANEOUS**

↑ ↑ ↑

24

HAYSMED

• **SYNOVITIS**



<https://my.dewandirect.org/health/diseases/synovitis>

25
