

Making Sense of Ulnar-sided Wrist Pain in Athletes

Ryan Xiao, MD May 9, 2026




Inside the Black Box



A partner for lifelong health

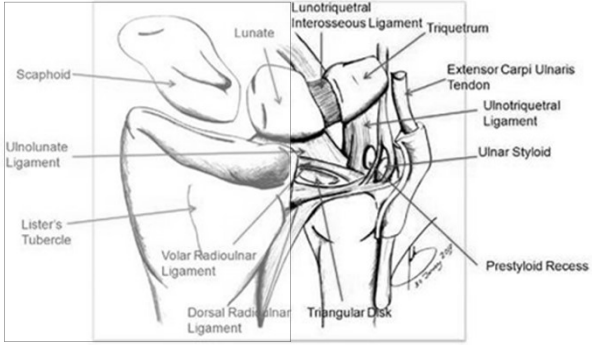
<p>Acute/Traumatic</p> <ul style="list-style-type: none"> - Hook of hamate tendonitis - TFCC tears ulnocarpal impaction - ECU instability Kienbock's disease - LT ligament injury Madelung deformity 	<p>vs</p>	<p>Chronic/Overuse</p> <ul style="list-style-type: none"> - ECU/FCU - - -
---	-----------	--




A partner for lifelong health

3

Soft Tissue Anatomyc





A partner for lifelong health

4

Ulnar Neutral
20% 80%

Ulnar Positive +2mm
40% 60%

Ulnar Negative -2mm
5% 95%

OrthoKansas
LMH Health

A partner for lifelong health 5

MRI Isn't Always the Answer

EDITOR'S CHOICE

The Prevalence of Triangular Fibrocartilage Complex Signal Abnormalities on Magnetic Resonance Imaging Relative to Clinical Suspicion of Pathology

Herb H. Beebe, BS; Kamran Oflazoglu, MD; Wouter F. van Leeuwen, MD; Husein Rahhou, MD, PhD; David Ring, MD, PhD; Neil C. Chen, MD

19% incidental TFCC tear in 18-30yo

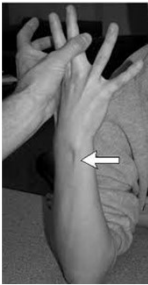Age Group	Incidental (%)	No signal changes (%)
18-30	20%	80%
31-40	30%	70%
41-50	30%	70%
51-60	45%	55%
61-70	45%	55%
>70	70%	30%

FIGURE 2: Signal changes in the TFCC on MRI nonsymptomatic cases (n = 861)

OrthoKansas
LMH Health

A partner for lifelong health 6

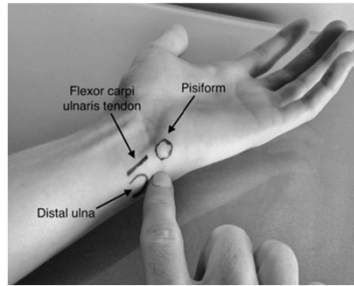
TFCC vs ECU



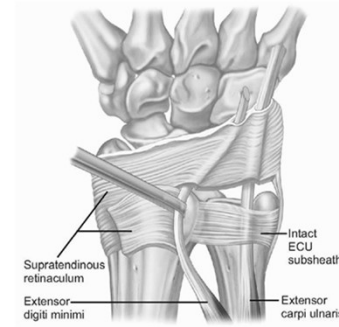
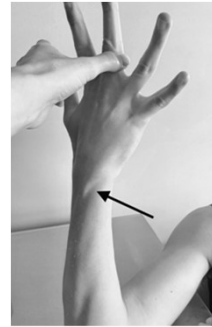
ECU Synergy Test = ECU



Fovea Tenderness = TFCC



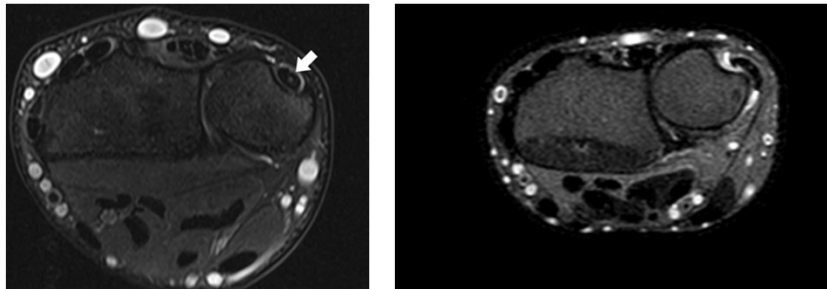
ECU Tendinitis



Non-op

*everyday of
the week &
twice on
Sunday*

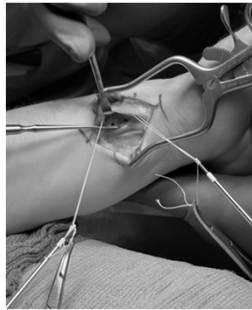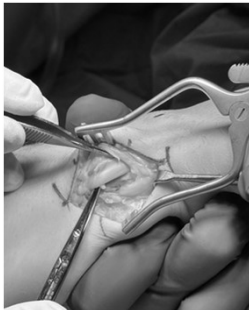
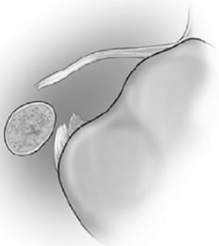
ECU instability



ECU instability

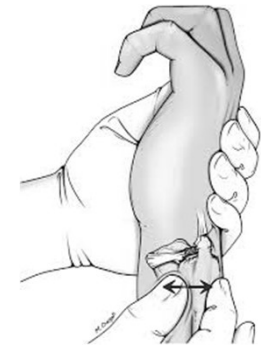

ECU instability

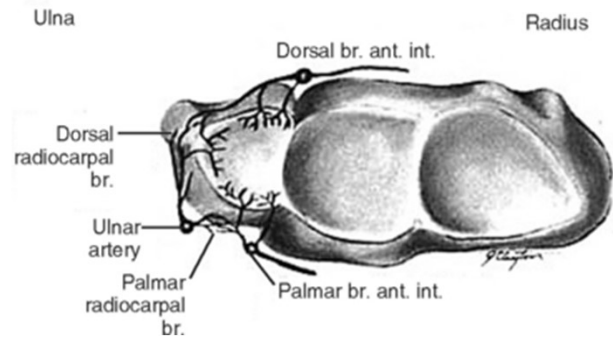


TFCC Injuries

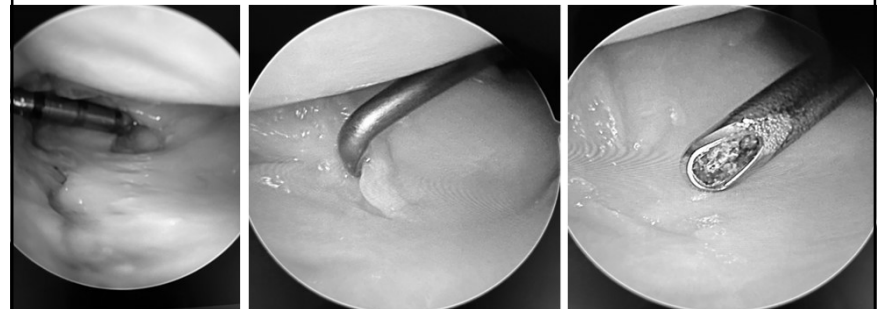
**DRUJ stability determines
debridement vs repair**



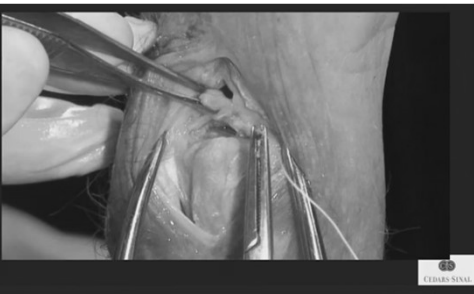
TFCC = meniscus of the wrist



Central TFCC Tear



Peripheral TFCC Tear



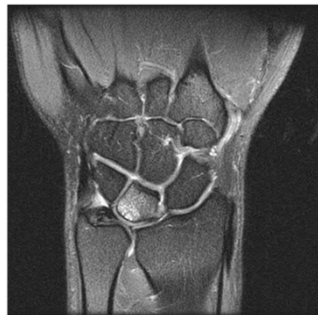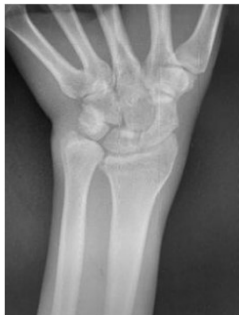TFCC tear
impaction



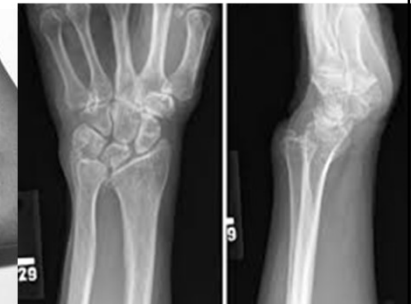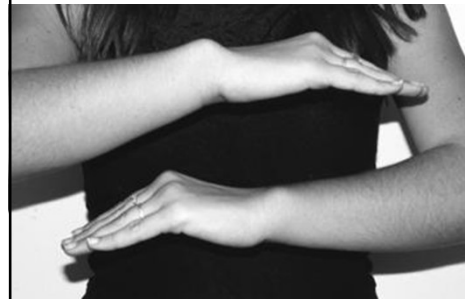TFCC tear + ulnocarpal



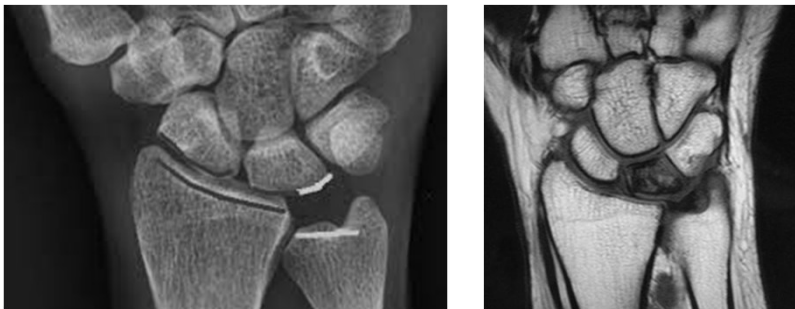Ulnocarpal Impaction Syndrome



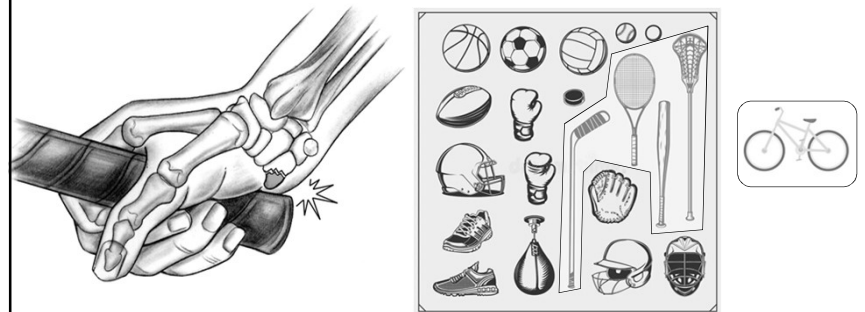
Madelung Deformity



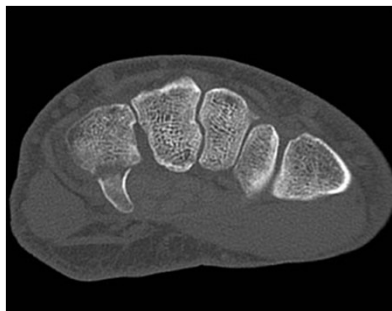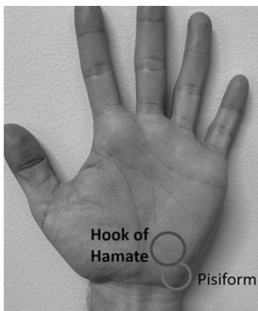
Kienbock's Disease



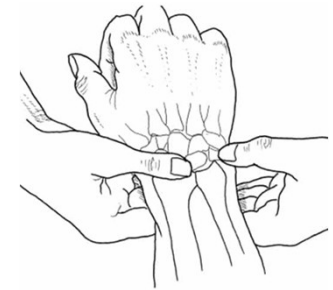
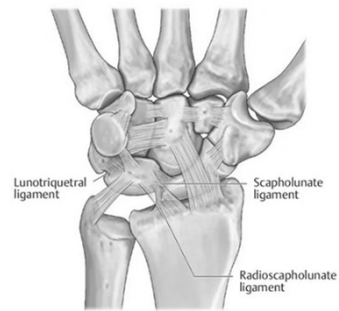
Hook of Hamate Fracture



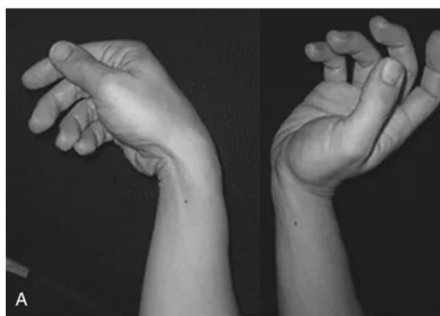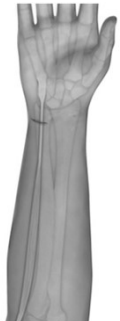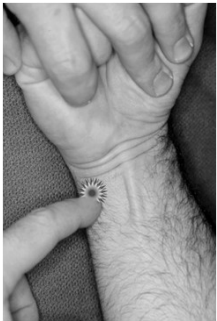Hook of Hamate Fracture



Lunotriquetral Injuries



FCU tendonitis



**Thank you to our sponsors
for support of the
2026 Sports Medicine Symposium
ARTHREX – ORTHOFIX –
VALD**

