

# Chronic Ankle Pain: An 18-year-old Recreational OSU Athlete

By Chase Cole, PT, DPT, CSCS



# Patient History

18 yo male recreational volleyball athlete

- **Current pain:** Right anterolateral ankle
- **Initial injury (9 months ago):** Eversion ankle sprain
- **Aggravating factors:** Prolonged walking, jumping and sprinting
- **Relieving factors:** Rest and initial movement
- **Past medical history:** Right hamstring strain
- **Imaging:** Radiographs of ankle joint - negative

## Initial Hypotheses

Fibularii Tendinopathy

Chronic Ankle Instability

Osteochondral Lesion of the  
Talus

Anterior Ankle Impingement

Lumbar Facet Hypermobility –  
Nerve Compression

Anterior Talofibular  
Ligament Sprain

## Top 3 Hypotheses

Chronic Ankle Instability

Anterior Ankle Impingement

Osteochondral Lesion of the  
Talus



# Examination

# Functional Analysis

## Standing

- Rearfoot varus

# Functional Analysis

Standing	Gait
<ul style="list-style-type: none"><li data-bbox="529 692 1072 753">• Rearfoot varus</li></ul>	<ul style="list-style-type: none"><li data-bbox="1296 692 1824 939">• Overpronation during stance phase</li></ul>

# Functional Analysis

## Double Leg Squat

- Pain at end range
- Weight shift
- Forward trunk lean

# Functional Analysis

Double Leg Squat	Single Leg Squat
<ul style="list-style-type: none"><li>• Pain at end range</li><li>• Weight shift</li><li>• Forward trunk lean</li></ul>	<ul style="list-style-type: none"><li>• Pain at end range</li><li>• Forward trunk lean descending</li><li>• Lateral trunk lean ascending</li></ul>

# Functional Analysis

Double Leg Squat	Single Leg Squat	Single Leg Heel Raise
<ul style="list-style-type: none"><li>• Pain at end range</li><li>• Weight shift</li><li>• Forward trunk lean</li></ul>	<ul style="list-style-type: none"><li>• Pain at end range</li><li>• Forward trunk lean descending</li><li>• Lateral trunk lean ascending</li></ul>	<ul style="list-style-type: none"><li>• Pain at end range</li><li>• Knee flexion</li><li>• Support needed</li></ul>

# Objective Examination

Range of Motion	Right	Left
Lumbar	Full	Full
Ankle Plantarflexion	50	55
Ankle Dorsiflexion (knee ext)	11	6
CKC Dorsiflexion	11 cm	10 cm

Strength	Right	Left	LSI (%)
Seated PF (HHD)	128.0 lbs	141.0 lbs	90.7%
SL Heel Raise	10 reps	25 reps	40%

# Objective Examination

Segmental Mobility	Right	Left
Talocrural Joint	Excess posterior glide	Within normal limits

Functional Testing	Right (composite)	Left (composite)
Y-Balance Test	100.4	104.6

# Evaluation

# Hypotheses Testing

## Chronic Ankle Instability

### Rule In:

- Laxity with anterior drawer & medial tilt test
- Altered performance in functional assessment

### Rule Out:

- No reports of instability or giving way
- No history of ankle sprains

# Hypotheses Testing

## Anterior Ankle Impingement

### Rule In:

- No reports of ankle instability or giving way
- Pain with squatting, running and jumping
- Anterolateral joint tenderness
- Pain with forced dorsiflexion
- Pain with end range plantarflexion

### Rule Out:

- No swelling

# Hypotheses Testing

## OC Lesion of Talus

### **Rule In:**

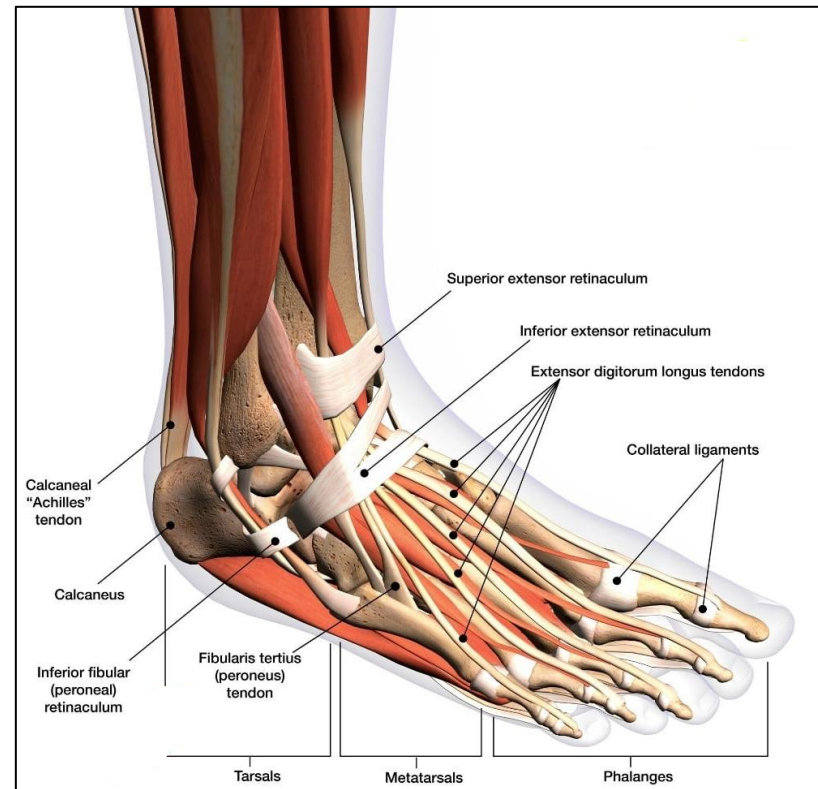
- Anterolateral joint tenderness
- Pain at end range double and single leg squat

### **Rule Out:**

- Negative radiographs
- No swelling
- No locking, catching, clicking or popping

# Assessment

- Final diagnosis: Anterior ankle impingement
- Pain generating tissue: Lateral talocrural joint



## Anterior Impingement CPR:

- ✓ Anterolateral joint tenderness
- Anterolateral joint swelling
- ✓ Pain with forced dorsiflexion
- ✓ Pain with single leg squat
- ✓ Pain with activity
- ✓ Absence of ankle instability

If 5 out of 6, then positive for anterior ankle impingement

- SN: 94%
- SP: 75%
- + LR: 3.8; - LR: 0.08

# Return to Sport (Full participation)

- Seated plantar flexion isometric strength > 90% LSI
- Single leg heel raise test > 90% LSI
- Y-balance test > 90% LSI
- Functional hop testing > 90%
- Less than 2/10 pain with all strength and sport specific tests

# Interventions

# Interventions

## Activity Modifications

- Allowed to play back row with no diving – limited participation

# Interventions

## Activity Modifications

- Allowed to play back row with diving – limited participation

## Proprioception

- Single leg static and dynamic balance



# Interventions

**Activity  
Modifications**

**Proprioception**

**Motor Control**



• play back row with no  
limited participation

• static and dynamic

- Step downs and single leg squats

# Interventions

Ac  
Modif

Propri

Motor


Strengthening



Allowed to pl  
diving – limite

Single leg sta  
balance

Step downs a



- Gastroc-soleus, fibularis, hip abductors, and quadriceps



**Outcomes**

# Outcome

- ✓ Seated plantar flexion isometric strength > 90% LSI
- ✓ Single leg heel raise test > 90% LSI
- ✓ Y-balance test > 90% LSI
- ✓ Functional hop testing > 90%
- ✓ Less than 2/10 pain with all strength and sport specific tests

# References

- Alahmari KA, Silvian P, Ahmad I, et al. Effectiveness of Low-Frequency Stimulation in Proprioceptive Neuromuscular Facilitation Techniques for Post Ankle Sprain Balance and Proprioception in Adults: A Randomized Controlled Trial. *BioMed Research International*. 2020;2020(1):9012930. doi:10.1155/2020/9012930
- Bowker S, Terada M, Thomas AC, Pietrosimone BG, Hiller CE, Gribble PA. Neural Excitability and Joint Laxity in Chronic Ankle Instability, Coper, and Control Groups. *J Athl Train*. 2016;51(4):336-343. doi:10.4085/1062-6050-51.5.05
- Camacho LD, Roward ZT, Deng Y, Latt LD. Surgical Management of Lateral Ankle Instability in Athletes. *J Athl Train*. 2019;54(6):639-649. doi:10.4085/1062-6050-348-18
- Diniz P, Sousa DA, Batista JP, Abdelatif N, Pereira H. Diagnosis and treatment of anterior ankle impingement: state of the art. *Journal of ISAKOS*. 2020;5(5):295-303.
- Lavery KP, McHale KJ, Rossy WH, Theodore G. Ankle impingement. *J Orthop Surg Res*. 2016;11(1):97.
- Lee C, Chen C. Role of proprioceptors in chronic musculoskeletal pain. *Experimental Physiology*. 2024;109(1):45-54. doi:10.1113/EP090989
- Martin RL, Davenport TE, Fraser JJ, et al. Ankle Stability and Movement Coordination Impairments: Lateral Ankle Ligament Sprains Revision 2021: Clinical Practice Guidelines Linked to the International Classification of Functioning, Disability and Health From the Academy of Orthopaedic Physical Therapy of the American Physical Therapy Association. *Journal of Orthopaedic & Sports Physical Therapy*. 2021;51(4):CPG1-CPG80. doi:10.2519/jospt.2021.0302
- Park YH, Park SH, Kim SH, Choi GW, Kim HJ. Relationship Between Isokinetic Muscle Strength and Functional Tests in Chronic Ankle Instability. *The Journal of Foot and Ankle Surgery*. 2019;58(6):1187-1191. doi:10.1053/j.jfas.2019.04.005

# References

- Physical Therapy After an Ankle Sprain: Using the Evidence to Guide Physical Therapist Practice. *Journal of Orthopaedic & Sports Physical Therapy*. 2021;51(4):159-160. doi:10.2519/jospt.2021.0503
- Picot B, Hardy A, Terrier R, Tassignon B, Lopes R, Fourchet F. Which Functional Tests and Self-Reported Questionnaires Can Help Clinicians Make Valid Return to Sport Decisions in Patients With Chronic Ankle Instability? A Narrative Review and Expert Opinion. *Front Sports Act Living*. 2022;4:902886. doi:10.3389/fspor.2022.902886
- Reiman MP. *Orthopedic Clinical Examination*. 1. Auflage. Human Kinetics; 2016
- Steele JR, Dekker TJ, Federer AE, Liles JL, Adams SB, Easley ME. Osteochondral lesions of the talus: current concepts in diagnosis and treatment. *Foot & Ankle Orthopaedics*. 2018;3(3):2473011418779559.
- Su Y, Li W, Pan C, Shi Y. Effects of combination of strength and balance training on postural control and functionality in people with chronic ankle instability: a systematic review and meta-analysis. *BMC Sports Sci Med Rehabil*. 2024;16(1):79. Published 2024 Apr 9. doi:10.1186/s13102-024-00845-1
- Talusan PG, Toy J, Perez JL, Milewski MD, Reach JS. Anterior Ankle Impingement: Diagnosis and Treatment. *Journal of the American Academy of Orthopaedic Surgeons*. 2014;22(5):333-339. doi:10.5435/JAAOS-22-05-333
- Terada M, Thomas AC, Pietrosimone B, Hiller CE, Bowker S, Gribble PA. The Consequence of a Medial Ankle Sprain on Physical and Self-reported Functional Limitations: A Case Study Over a 5-Month Period. *Journal of Orthopaedic & Sports Physical Therapy*. 2015;45(10):756-764. doi:10.2519/jospt.2015.6097
- Wenning M, Schmal H. Chronic Ankle Instability - Mechanical vs. Functional. *Z Orthop Unfall*. 2023;161(05):552-562. doi:10.1055/a-1696-2503